

# Evolution of Endovascular Management of Common Iliac Artery Aneurysms

With newer-generation devices and increasing operator experience, there is potential to broaden the scope of EVAR for iliac artery aneurysms.

BY TIFFANY WU, MD, AND JASON T. LEE, MD

Endovascular aneurysm repair (EVAR) has evolved to become the first choice in the treatment for patients with thoracic and abdominal aortic aneurysms (AAAs). Despite the success of endovascular techniques for abdominal and thoracic pathology, management of aortoiliac aneurysms (AIAs) remains challenging, with up to 30% of AAAs having concomitant common iliac artery aneurysms (IAAs). Typical strategies utilized during standard endovascular repair of AIA involve sacrifice via embolization of unilateral or bilateral hypogastric arteries (HAs). This can lead to complications including buttock claudication, erectile dysfunction, and colon ischemia.

Several novel endovascular techniques have been proposed to preserve the HAs, including “bell-bottom” iliac limbs, the sandwich or double-barrel technique, the cross-chimney technique, and, more recently, the development of iliac branch devices (IBDs). IBDs have been designed as a purpose-specific treatment and have reported high technical success rates. The main concern with IBDs has been their relatively strict anatomic inclusion criteria and the fact that no devices have been approved for this indication by the US Food and Drug Administration as of February 2016. Newer-generation designs and increasing experience may broaden its application scope.

## EPIDEMIOLOGY AND CLINICAL PRESENTATION

It is common that AAAs extend to the iliac artery, with the incidence estimated at 20% to 30%.<sup>1,2</sup> Hence, nearly one-third of all patients being considered for standard EVAR might not fit within the instructions for use (IFU) without adjunctive measures due to a lack of seal at the enlarged iliac landing zone. Fortunately, isolated IAAs without AAA are uncommon. Autopsy estimates document rates of 0.03% for IAA, and in clinical series, the prevalence ranges from 2.2% to 7.8%.<sup>3,4</sup>

Most patients with IAA and concomitant AAA or isolated IAA are asymptomatic and are incidentally detected on imaging studies. Owing to the deep pelvic location, symptoms including local visceral or venous compression, neuropraxia,

or rupture may not occur until the aneurysms reach a considerable size.<sup>5</sup> IAAs tend to be more symptomatic at larger maximum diameters, and the risk of rupture with isolated IAAs is high (up to 29%).<sup>6</sup> The natural history of isolated IAAs is progressive expansion at a rate dependent on the size of the aneurysm: IAAs smaller than 3 cm expand at an average rate of 0.05 to 0.15 cm/year, whereas aneurysms larger than 3 cm increase at up to 0.28 cm/year. IAA rupture is usually a life-threatening emergency that can lead to hemorrhagic shock and death without intervention. The current consensus is that elective repair should be considered in good-risk patients for isolated IAAs > 3 cm in maximum transverse diameter due to an increasing risk of developing symptoms, including rupture.<sup>7</sup>

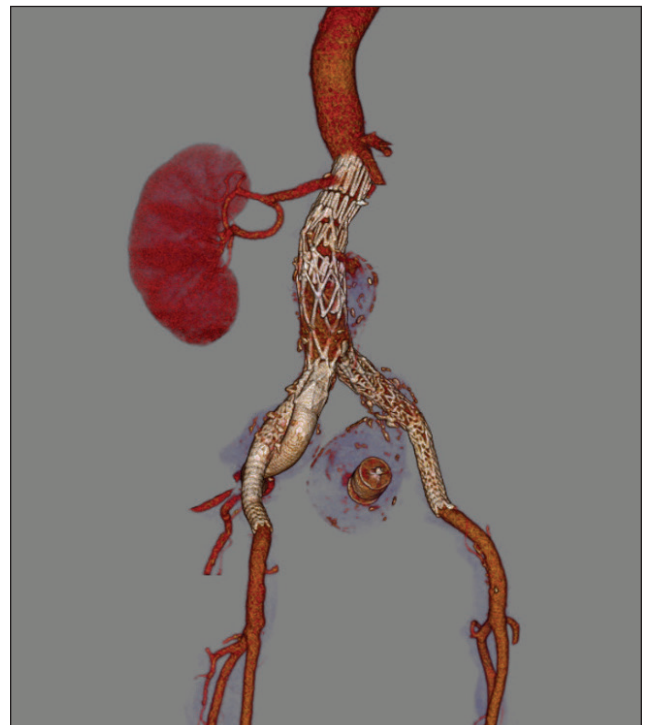


Figure 1. EVAR with embolization.

## EVAR WITH EMBOLIZATION

Historically, interventional occlusion of the HA has commonly been applied in patients undergoing EVAR, especially when the aneurysmal process extends to one or both of the iliac artery bifurcations.<sup>8</sup> Figure 1 illustrates an example of coil embolization during EVAR. Several reports have focused on the feasibility and safety of HA embolization. According to these studies, patient age and functional status, unilateral or bilateral status, and the embolization position (main trunk or branch) are the three primary influencing factors affecting clinical outcomes. Coils and ST. JUDE AMPLATZER Vascular Plugs to facilitate otherwise routine EVAR have been described and utilized, and although there is no doubt that HA embolization prior to EVAR has increased the number of patients suitable for EVAR, it is associated with significant risk of pelvic ischemia and other side effects, as noted in the following section. To decrease such side effects, it is reasonable to preserve flow in at least one HA, as per Society for Vascular Surgery guidelines,<sup>9</sup> select patients in whom symptoms are less bothersome, or to employ strategies to preserve both HAs whenever possible, especially in young patients.

## INTERNAL ILIAC PRESERVATION

The internal iliac artery (IIA) or HA is the dominant artery in the pelvic region, supplying blood flow to the hips, thighs, left colon, and the reproductive organs. Sacrifice of either the unilateral or bilateral HA can lead to several complications, the most common of which is buttock claudication, with incidences ranging from 1.6% to 56%.<sup>10</sup> Colonic ischemia is another feared pelvic ischemic complication of HA occlusion, with associated mortality and an incidence as high as 9%.<sup>11,12</sup> Because the inferior mesenteric artery is routinely sacrificed during EVAR, loss of collateral circulation from embolization of one or both HAs can have detrimental effects on the blood supply of the distal and sigmoid colon. New-onset erectile dysfunction has also been found to occur in up to 33% of patients undergoing HA occlusion.<sup>13</sup> Although not life-threatening, this complication of HA occlusion is considered by some patients to be quite compromising to their overall quality of life, especially in the 15% of patients who suffer from persistent symptoms.<sup>14</sup> Other rare but devastating complications following HA occlusion include spinal cord ischemia, buttock necrosis, scrotal skin ulceration, and sciatic nerve ischemia.<sup>15,16</sup> These factors should be taken into consideration when planning for EVAR, and early efforts to address these complications came in the form of bell-bottom limbs.

## BELL-BOTTOM TECHNIQUE

The bell-bottom technique, also known as the *flared limb technique*, may currently be the most commonly used technique to preserve flow into the IIA during EVAR, particularly now with the increased availability of larger-

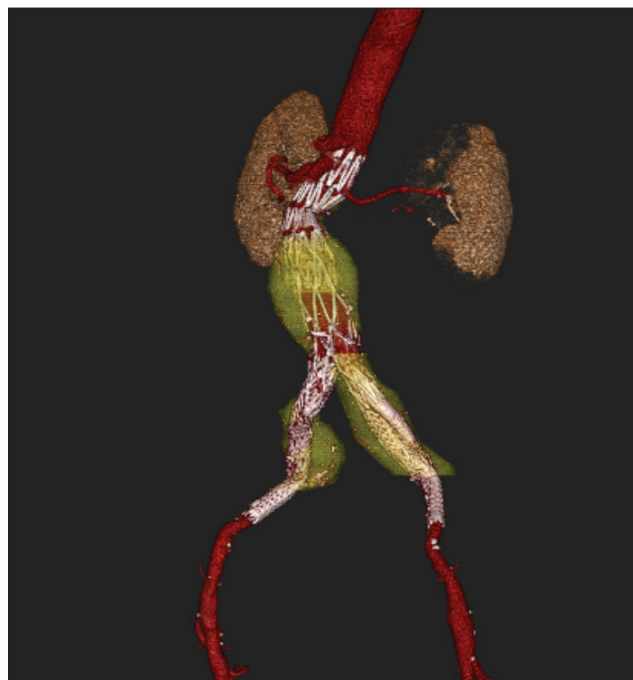

Figure 2. The sandwich/double-barrel/internal iliac snorkel technique.

diameter iliac limbs. One can also use an aortic cuff, which has a maximum diameter of 36 mm. This technique assumes the dilated common iliac artery (CIA) as the healthy vessel and entails the use of a large-diameter iliac extension limb to seal the distal CIA in order to preserve the IIA. The advantages of this technique include its relative ease of use, accessibility, high technical success rates (described as high as 97%), and low type Ib endoleak rate (reported as low as 2%–4%).<sup>17,18</sup> Most manufacturers provide iliac limbs of 27 to 28 mm, which can only seal in CIA diameters of up to 25 mm. As previously noted, aortic cuffs have also been used by physicians as iliac extensions for the treatment of slightly larger-diameter common IAAs (up to 30 mm). However, the long-term durability of the bell-bottom technique is unclear, as some have raised concerns over further aneurysmal dilation of the iliac artery with resultant stent-graft migration and type Ib endoleak.<sup>19</sup> In seeking more durable repair, physicians began employing various “sandwich” or “snorkel” techniques to gain more distal sealing in nonaneurysmal tissue.

## SANDWICH/DOUBLE-BARREL/INTERNAL ILIAC SNORKEL TECHNIQUE

The sandwich technique, also called the *double-barrel technique*, has been proposed as an alternative endovascular method to preserve the ipsilateral HA when treating CIAAs extending to or involving the iliac bifurcation (Figure 2).<sup>20</sup> As originally described by Lobato, the sandwich technique preserves either unilateral or bilateral

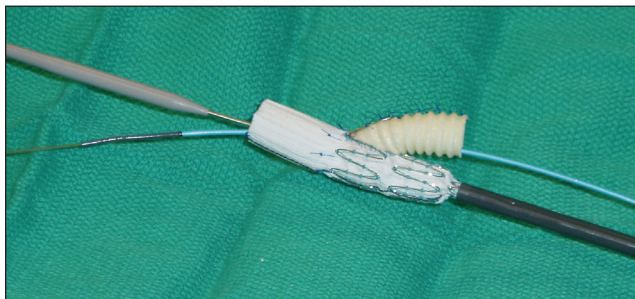


Figure 3. A physician-modified device.

IAs. Several modifications to the technique have since been described, including avoiding arm access, use of unibody devices, and mixing of peripheral stent-grafts and EVAR limbs. DeRubertis et al<sup>21</sup> reported a technical success rate of 88% in 22 patients, with 9% early type III endoleaks between parallel stent-graft components. Early limb occlusion occurred in 9% (one in the external iliac artery [EIA], two in the HA), with primary patency for EIA and HA limbs at 6 months of 95% and 88%, respectively. Lobato et al reported better midterm outcomes in a more recent cohort of 40 patients, with a technical success rate of 100% and a primary patency rate of 93.8% (three HA occlusions).<sup>22</sup> The main advantages of the sandwich technique include the lack of size restrictions (ie, CIA diameter, HA length or diameter), lower potential cost, relative ease of the procedure, and the immediate availability of stent-grafts. However, potential concerns include gutter-related endoleaks and long-term limb patency.

### **SURGEON-MODIFIED/HOMEMADE GRAFTS**

All of the aforementioned techniques are not purpose-specific solutions for the treatment of iliac aneurysms. Thus, it was obvious that industry would create IBDs to treat down to and include the EIA and HA. Although patients in many other countries have benefited from this technology for more than a decade, IBDs are still (as of February 2016) not commercially available in the United States. Like many of the previously described endovascular innovations, there were creative solutions sought in the United States, including several reports of homemade devices, with Oderich and Ricotta first describing the method of surgeon-modified IBDs for IAA treatment. Polyester or PTFE vascular grafts of 7 to 8 mm were sewn onto limbs, and either a self-expanding covered stent-graft or balloon-expandable covered stent-graft (ATRIUM® iCAST® Covered Stent) could be chosen as the bridging stents (Figure 3).<sup>23</sup> There has been a high technical success rate reported, and the short-term follow-up has been without issue, although it is limited to a small number of case reports. The basic limitation of this technique involves the regulatory issues involved in modification of a device and performing this electively without an investigational device exemption.

### **TRIFURCATION TECHNIQUE**

The trifurcation technique, first described by Minion et al, employs the use of multiple main body bifurcated endografts.<sup>24</sup> Conceptually, the modular graft is built down from the renal arteries rather than up from the iliac arteries. This method, originally requiring bilateral femoral access in addition to brachial access, uses a “top-down” approach to facilitate cannulation of the HA, although later modifications allowed all femoral access. As described in the literature, after securing the infrarenal neck and placing a flared 20-mm-diameter limb into the proximal common iliac, a second 23-mm main body diameter GORE® EXCLUDER® AAA Endoprosthesis creates another bifurcation at the distal common iliac aneurysm, allowing a GORE® VIABAHN® Endoprosthesis to then be deployed to seal into the HA (Figure 4). The anatomic limitations of the trifurcated configuration are that it requires a large enough distal aortic diameter to fit the three limbs and a minimum of 16.5 cm in length from the lowest renal artery to the HA origin. Other possible disadvantages include higher procedural cost due to the use of multiple main bodies, increased length and complexity of procedure, and increased amount of contrast used.

### **ILIAC BRANCH DEVICES**

The GORE® EXCLUDER® Iliac Branch Endoprosthesis (IBE) is based upon the GORE® EXCLUDER® Device platform and has a modular concept of an iliac branch component mated to a bridging stent into the HA. The device is composed of two components: the Iliac Branch Component and the Internal Iliac Component. The Iliac Branch Component can be repositioned during deployment (via a two-stage deployment) to aid in internal iliac artery cannulation and to ensure accurate device placement. Additionally, the Iliac

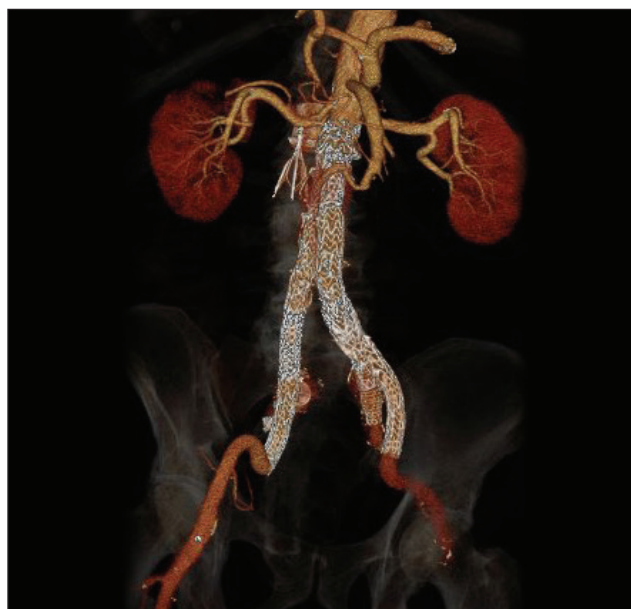

Figure 4. A trifurcation.



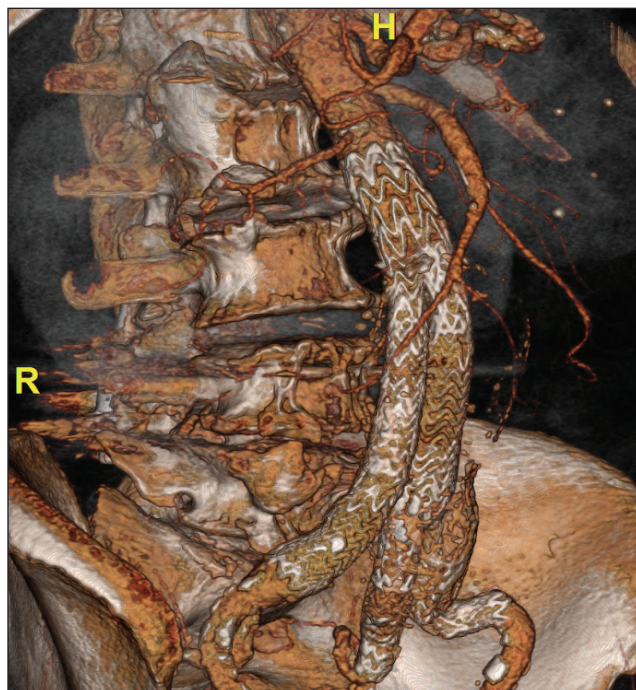

Figure 5. The GORE® EXCLUDER® Iliac Branch Endoprosthesis.

Branch Component features pre-cannulation of the IIA gate, which aids in ease of use. The devices also offer a broad treatment range, including an EIA treatment range of 6.5 to 25 mm and an IIA treatment range of 6.5 to 13.5 mm. The IBE is designed to be used with the GORE EXCLUDER Device, a AAA endograft with extensive commercial worldwide experience. Overall, the features and design of the IBE offer an all-in-one, user-friendly system that can preserve blood flow to the IIA while providing a durable solution for aneurysm exclusion.

Through 6 months, the results from the United States clinical trial demonstrate that the device offers an effective treatment for these patients with common iliac or aortoiliac aneurysms. Based on site-reported data for 62 patients enrolled during the primary enrollment, the United States clinical trial has shown an overall technical success rate of 95.2%, with an average procedure time of 151.8 minutes for implantation of both the IBE and GORE EXCLUDER Device (Figure 5). There have been no AAA enlargements (0%) reported through 6 months, with 100% patency of the EIA and 95% patency of the HA at 6 months. Additionally, there have been no reports of buttock claudication (0%) on the IBE treatment side and no reports of new-onset sexual dysfunction (0%). There was one reintervention through 6 months to address an EIA dissection distal to a bare-metal stent that was placed as a distal extension to the IBE during the index procedure. These data points are supported by commercial European experience, with reports demonstrating high technical success and positive clinical outcomes while avoiding complications related to sacrificing blood flow to the HA.<sup>25,26</sup>

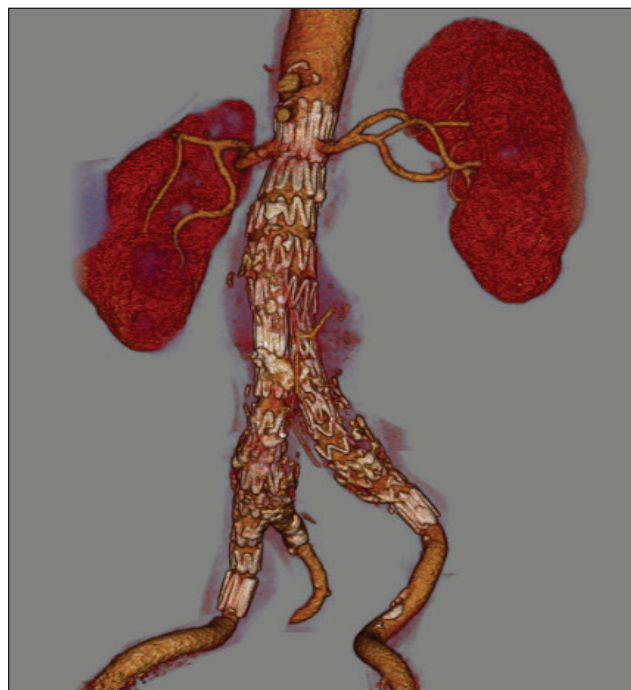

Figure 6. The COOK® ZENITH® Iliac Branch Endoprosthesis.

The COOK® ZENITH® Iliac Branch Endoprosthesis consists of a side branch mounted on the medial side of an iliac limb stent-graft. An indwelling wire passing through the IIA branch can be snared from the contralateral femoral artery to create a through-and-through wire to allow for catheterization of the HA and stable positioning of a sheath to deliver the bridging component. The straight side arm has a relatively short (~14 mm) overlap zone that is intended for use with the balloon-expandable ATRIUM iCAST Covered Stent (Figure 6).

Since its initial conception, results associated with IBDs gradually improved with newer-generation devices and improved experience. In a literature review by Karthikesalingam et al,<sup>27</sup> nine series utilizing IBD (all being the Cook Medical IBD platform, including the COOK ZENITH Iliac Branch Endoprosthesis) were included, and early technical success was between 85% and 100% in these series. The review also revealed a collective 12% IBD limb occlusion rate, of which, 50% developed buttock claudication. In this review, the reported type I and III endoleaks were only 1.6%.

## ANATOMIC SUITABILITY

As of February 2016, there are two iliac branch pivotal trials enrolling in the United States: the COOK PRESERVE-ZENITH® Iliac Branch System Clinical Study and the GORE EXCLUDER Iliac Branch Device Clinical Study. Based on the favorable experience noted in the previously mentioned clinical trials, as well as the author's personal experience and participation in both trials, US Food and Drug Administration approval for this important technology is on the horizon. As with any new

endovascular technology, however, careful patient selection is essential to technical success and durable outcomes, as not all the patients are anatomically suitable for these devices. Severe iliac tortuosity and aneurysmal involvement of the IIA can lead to increased procedural challenges and higher rates of type I and III endoleaks, as can issues with length, iliac stenosis, and angulation at the distal aorta.<sup>28</sup>

Studying the IFU for both devices that are currently in trial, there are some differences. The basic anatomic criterion of the COOK ZENITH Iliac Branch Endoprosthesis IFU include: EIA length > 20 mm, EIA diameter between 8 and 11 mm, HA length > 10 mm, HA diameter of 6 to 9 mm, and CIA length > 50 mm. The anatomic criterion of the GORE EXCLUDER Iliac Branch Endoprosthesis are mainly: CIA diameter > 17 mm, distance between the lowest renal artery and the iliac bifurcation > 165 mm, iliac bifurcation diameter > 14 mm, and HA diameter of 6 to 14 mm. Both devices are delivered using reasonably low-profile sheaths that are associated with high conformability in order to offer good adaptation, even in tortuous iliac arteries.

In a study conducted out of the University of Alabama Birmingham and Stanford,<sup>29</sup> Pearce et al found that if one strictly complies with the manufacturer's IFU, only about one-third of patients with IAAs treated over the past decade at those institutions would have been suitable for treatment with an IBD. The primary reasons for exclusion included dilated HA diameters, inadequate HA landing zones, and stenotic proximal CIAs. Although this was only a hypothetical study looking at inclusion/exclusion criteria, the anatomic fit was similar for the IBE and the COOK ZENITH Iliac Branch Endoprosthesis (25% vs 18%, respectively), while the anatomic fit was approximately 35% when assessed using combined criteria for both devices.

## CONCLUSION

Up to 40% of AAAs have concomitant IAA disease, compromising the distal seal during standard EVAR. Although initially thought to be somewhat innocuous, the loss of HA patency has some ramifications, and EVAR technology has now evolved to be able to preserve hypogastric flow. Off-the-shelf creative solutions with standard EVAR devices, limbs, and peripheral stent-grafts in parallel configurations or with multiple main bodies all demonstrate good technical success and durability. However, the advent and inevitable approval of purpose-specific devices for iliac aneurysms should make these devices part of the armamentarium of the endovascular specialist. The main challenge of the current IBDs is their applicability to difficult anatomy. Future-generation design modifications, improved branch and bridging stents, and increasing experience may broaden its indication and likely improve results in the future. ■

*Tiffany Wu, MD, is a vascular fellow at Stanford University Medical Center in Stanford, California. She has stated that she has no financial interests related to this article.*

*Jason T. Lee, MD, is Professor of Surgery, Director of Endovascular Surgery, Program Director, Vascular Surgery Residency/Fellowship, Division of Vascular Surgery, Stanford University Medical Center in Stanford, California. He has disclosed that he is the site Principal Investigator at Stanford for both the GORE EXCLUDER Iliac Branch Device Clinical Study and COOK PRESERVE-ZENITH® Iliac Branch System Clinical Study. Dr. Lee may be reached at [jtleee@stanford.edu](mailto:jtleee@stanford.edu).*

- Armon MP, Wenham PW, Whitaker SC, et al. Common iliac artery aneurysms in patients with abdominal aortic aneurysms. *Eur J Vasc Endovasc Surg*. 1998;15:255-257.
- Henretta JP, Karch LA, Hodgson KJ, et al. Special iliac artery considerations during aneurysm endografting. *Am J Surg*. 1999;178:212-218.
- Brunkwall J, Hauksson H, Bengtsson H, et al. Solitary aneurysms of the iliac arterial system: an estimate of their frequency of occurrence. *J Vasc Surg*. 1989;10:381-384.
- Bacharach JM, Slovut DP. State of the art: management of iliac artery aneurysmal disease. *Catheter Cardiovasc Interv*. 2008;71:708-714.
- Patel NV, Long GW, Cheema ZF, et al. Open vs. endovascular repair of isolated iliac artery aneurysms: a 12-year experience. *J Vasc Surg*. 2009;49:1147-1153.
- Chae RA, Barbato JE, Lin SC, et al. Isolated iliac artery aneurysms: a contemporary comparison of endovascular and open repair. *J Vasc Surg*. 2008;47:708-713.
- Huang Y, Glaviczki P, Duncan AA, et al. Common iliac artery aneurysm: expansion rate and results of open surgical and endovascular repair. *J Vasc Surg*. 2008;47:1203-1210; discussion 1210-1211.
- Jean-Baptiste E, Brizzi S, Bartoli MA, et al. Pelvic ischemia and quality of life scores after interventional occlusion of the hypogastric artery in patients undergoing endovascular aortic aneurysm repair. *J Vasc Surg*. 2014;60:40-49.
- Chalkof EL, Brewster DC, Dalman RL, et al. The care of patients with an abdominal aortic aneurysm: The Society for Vascular Surgery practice guidelines. *J Vasc Surg*. 2009;50:S2-S49.
- Bekdache K, Dietzek AM, Cha A, Neychev V. Endovascular hypogastric artery preservation during endovascular aneurysm repair: a review of current techniques and devices. *Ann Vasc Surg*. 2015;29:367-376.
- Bratby MJ, Munneke GM, Belli AM, et al. How safe is bilateral internal iliac artery embolization prior to EVAR? *Cardiovasc Interv Radiol*. 2008;31:246-253.
- Verzini F, Parlani G, Romano L, et al. Endovascular treatment of iliac aneurysm: concurrent comparison of side branch endograft versus hypogastric exclusion. *J Vasc Surg*. 2009;49:1154-1161.
- Farahmand P, Becquemin JP, Desgranges P, et al. Is hypogastric artery embolization during endovascular aortoiliac aneurysm repair (EVAR) innocuous and useful? *Eur J Vasc Endovasc Surg*. 2008;35:429-435.
- Rayt HS, Bown MJ, Lambert KV, et al. Buttock claudication and erectile dysfunction after internal iliac artery embolization in patients prior to endovascular aortic aneurysm repair. *Cardiovasc Interv Radiol*. 2008;31:728-734.
- Eagleton MJ, Shah S, Petkosevek D, et al. Hypogastric and subclavian artery patency affects onset and recovery of spinal cord ischemia associated with aortic endografting. *J Vasc Surg*. 2014;59:89-94.
- Oderich GS, Greenberg RK. Endovascular iliac branch devices for iliac aneurysms. *Perspect Vasc Surg Endovasc Ther*. 2011;23:166-172.
- Naughton PA, Park MS, Khirelsey EA, et al. A comparative study of the bell-bottom technique vs hypogastric exclusion for the treatment of aneurysmal extension to the iliac bifurcation. *J Vasc Surg*. 2012;55:956-962.
- Torsello G, Schönefeld E, Osada N, et al. Endovascular treatment of common iliac artery aneurysms using the bell-bottom technique: long-term results. *J Endovasc Ther*. 2010;17:504-509.
- Alvarez Marcos F, García de la Torre A, Alonso Pérez M, et al. Use of aortic extension cuffs for preserving hypogastric blood flow in endovascular aneurysm repair with aneurysmal involvement of common iliac arteries. *Ann Vasc Surg*. 2013;27:139-145.
- Lobato AC. Sandwich technique for aortoiliac aneurysms extending to the internal iliac artery or isolated common/internal iliac artery aneurysms: a new endovascular approach to preserve pelvic circulation. *J Endovasc Ther*. 2011;18:106-111.
- DeRubertis BG, Quinones-Baldrich WJ, Greenberg JJ, et al. Results of a double-barrel technique with commercially available devices for hypogastric preservation during aortoiliac endovascular abdominal aortic aneurysm repair. *J Vasc Surg*. 2012;56:1252-1259.
- Lobato AC, Camacho-Lobato L. Camacho-Lobato, The sandwich technique to treat complex aortoiliac or isolated iliac aneurysms: results of midterm follow-up. *J Vasc Surg*. 2013;57(2 suppl):265-345.
- Oderich GS, Ricotta JJ 2nd. Novel surgeon-modified hypogastric branch stent graft to preserve pelvic perfusion. *Ann Vasc Surg*. 2010;24:278-286.
- Minion DJ, Xenos E, Sorial E, et al. The trifurcated endograft technique for hypogastric preservation during endovascular aneurysm repair. *J Vasc Surg*. 2008;47:658-661.
- Schönhofer S, Mansour R, Ghotbi R. Initial results of the management of aortoiliac aneurysms with Gore Excluder Iliac Branched Endoprosthesis. *J Cardiovasc Surg*. 2015;56:883-888.
- Ferrer C, De Crescenzo F, Coscarella C, et al. Early experience with the Excluder iliac branch endoprosthesis. *J Cardiovasc Surg*. 2014;55:679-683.
- Karthikesalingam A, Hinchliffe RJ, Holt PJ, et al. Endovascular aneurysm repair with preservation of the internal iliac artery using the iliac branch graft device. *Eur J Vasc Endovasc Surg*. 2010;39:285-294.
- Karthikesalingam A, Hinchliffe RJ, Malkawi AH, et al. Morphological suitability of patients with aortoiliac aneurysms for endovascular preservation of the internal iliac artery using commercially available iliac branch graft devices. *J Endovasc Ther*. 2010;17:163-171.
- Pearce BJ, Varu VN, Glocker R, et al. Anatomic suitability of aortoiliac aneurysms for next generation branched systems. *Ann Vasc Surg*. 2015;29:69-75.